

Endodontic retreatment of an upper molar with periradicular perforation and lesion

Dr. Emanuele Ambu, M.D., D.D.S.,
Clinical Assistant Professor, Tuscan School of Dental Medicine University of Siena, Italy; Dept. of Endodontics (Chairman: Prof. Simone Grandini);
Visiting Professor at: University of Valencia for the Master's Degree in Endodontics (Chairman: Prof. Leopoldo Forner).

Introduction

Endodontic retreatment diseases are almost always accompanied by periradicular bone lesions, often with pain and apostematous manifestations. Retreatment is the best therapy to solve this problem, achieving positive results in more than 85% of cases. The aim of endodontic retreatment is to reduce intracanal bacterial contamination below the critical threshold following these procedures:

- Isolation with rubber dam;
- Proper opening of access cavity and canal orifices;
- Complete shaping of all canal systems;
- Cleaning with appropriate irrigants;
- Complete filling of the root canal system;
- Filling the access cavity with permanent material.

Retreatment prognosis is less favourable than that of conventional endodontic treatment because several bacteria, like *Enterococcus faecalis* and *Treponema denticola* appear to be more resistant to the chemical agents used to clean, and can penetrate the dentinal tubules. They are also resistant to long periods of "starvation".

Under these conditions, the risk of recontamination can be reduced using materials or techniques ensuring more effective sealing of the root canal system, increasing the percentage of success of the endodontic therapy.

Warm gutta percha is considered the "gold standard" to fill the root canal system; but it contracts while cooling down and this forms a gap between the root canal walls and gutta

percha so that the bacteria of dentinal tubules can contaminate canals again.

To solve this problem, a cold-filling technique based on bioceramics has been recently introduced. This material was initially suggested to replace mineral trioxide aggregate in various cases (radicular perforations, apexifications, direct capping of the pulp, etc.), because MTA had some problems: it took long to harden and it was unsuitable to be in touch with the oral environment.

Clinical Case

A male Caucasian patient VL aged 48 was referred by a colleague who did not manage to probe the root canals, after many attempts, had not succeeded in probing the canals of his right upper molar, which had been unadequately filled during previous treatments. There was also a perforation altering the pathway of the mesio-vestibular canal. The clinical picture was further complicated by two vestibular fistulae secreting pus. Endoral RX and CBCT examination (*Fig. 1*) -- performed to better understand the functioning of root canals -- showed widespread periradicular lesions and an inflammation of the male breast, with likely odontogenous origin.

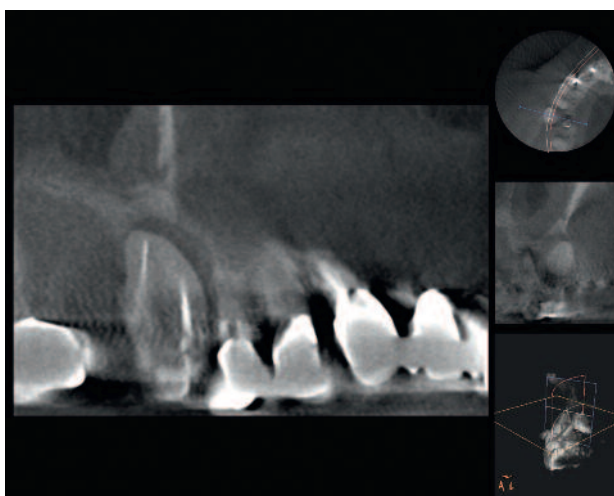


Fig. 1

More recently, a new preparation has permitted the use of bioceramics as an endodontic filling material.

The aim of this paper is to describe a complex example of molar retreatment treated by means of BioRoot™ RCS, a canal filling material sold by Septodont (Saint-Maur-des-fossés, France).

While the palatal and mesio-vestibular canals were easily renegotiable, it was not possible to restore the correct course of the mesio-vestibular canal. Using a surgical microscope, it was possible to locate the orifice of the mesio-palatal canal (*Fig. 2, arrow*), not detected in the two preceding treatments. This canal was found to be confluent with the mesio-vestibular, thus permitting recovery of the entire course, which appeared anomalous compared to the usual endodontic anatomy of the first upper molar. Following a thorough cleaning of the root canal system, the practitioner filled the entire system using cold tapered gutta percha points (06) and

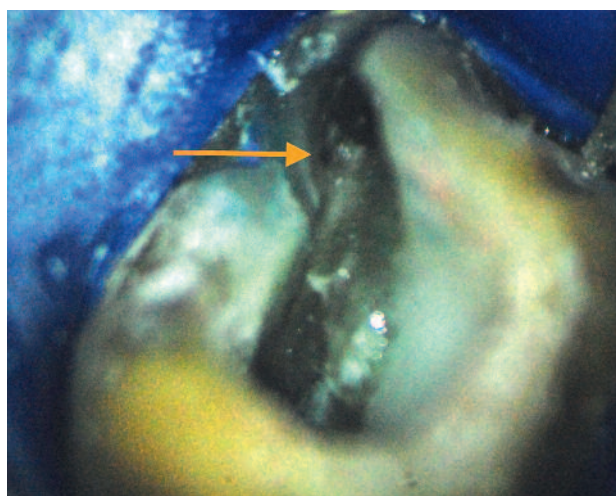


Fig. 2

BioRoot™ RCS cement (*Fig. 3*). The control after seven months showed that the periradicular lesion had almost disappeared and the

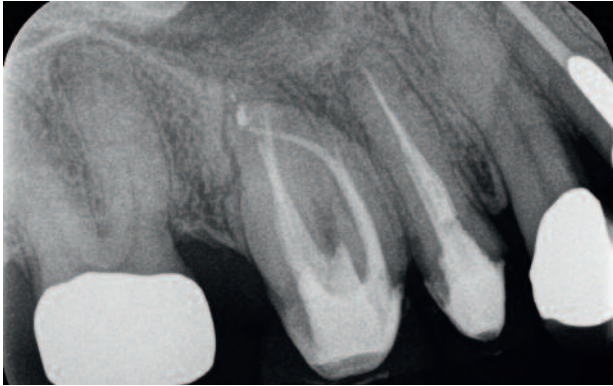

Fig. 3

renewed pneumatisation of the maxillary sinus (*Fig. 4*). Subsequent examination is anticipated 12 months after completion of treatment.

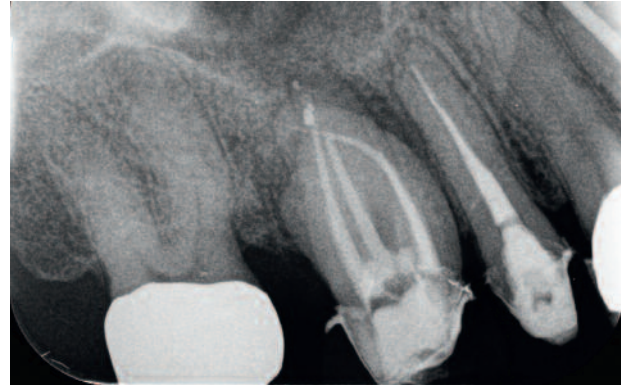


Fig. 4

Discussion

Bioceramics are today quite well-known materials in the literature, especially because they can replace mineral trioxide aggregate.

Biodentine™, defined as an active biosilicate, is bioactive and continues to produce hydroxyapatites long after blending. It can therefore fit the dentinal walls and improve its sealing capacity. BioRoot™ RCS -- a product obtained after testing these materials -- can ensure complete sealing of the root canal system after full cleaning and shaping. It is also an effective antibacterial agent. Its biocompatibility has been recently evaluated in several studies, but there is no research published about the clinical effects of this material. It is a very interesting material because it perfectly adheres to both dentine and gutta percha, so that it can be used in cold sealing techniques.

Conclusion

The case described above shows how it is possible to have excellent canal filling even in anatomically complex or compromised situations. Thanks to the excellent sealing capacity of bioceramics the periradical tissues can recover

This cannot be considered a monocone technology: in this technique, a single gutta percha cone is inserted into the canal -- which has [already] been filled with endodontic cement -- in an attempt to occupy the major part of the volume of the root canal. Since the endodontic cement is absorbable with time, this technology was [traditionally] considered highly ineffective, and not recommended by many practitioners. On the other hand, in cold sealing technology using bioceramics, the cement plays an important role because it is truly active in sealing the canal. The gutta percha cone -- which must be inserted quite deeply, near the apex -- is the only material which permits retreatments in the event of technical errors.

rapidly. Prospective clinical studies must in any case be conducted to evaluate the effectiveness of this technique, both in the medium and the long term.



Author:

Dr. Emanuele Ambu

1989, Graduated from Medicine and Surgery at the University of Bologna;
1998, Attend advanced post-graduate courses at the University of Florence.
2002-2003, Teaching of dental subjects at the University of Modena-Reggio Emilia
2005-2006, Coordinator of the Post-graduate Course in endodontics
2006-2008, obtain Master Degree in Endodontics at the University of Bologna
2011-2013, visiting professor at the Tuscan School of Medicine, University of Siena.
2013, visiting professor at the University of Cagliari.

Dr. Emanuele Ambu is currently (2016) a visiting professor in the teaching of “Retrograde Endodontics” at the Tuscan School of Medicine, University of Siena. He is also a visiting professor for the Master's Degree in Endodontics and the Master's Degree in Endodontics at the Universitat de Valencia.

Dr. Emanuele Ambu has published various articles on endodontic subjects for both Italian and international journals. He is a reviewer for the journal International Journal of Pediatric Dentistry, [as well as] for the journal *Advances in Radiology* and for the site Online Endo Academy. Speaker in courses and congresses in Italy and foreign countries since 1995. He works in his independent praxis in bologna as an endodontist and oral surgeon.

Download the complete series

Septodont Case Studies Collection

www.septodont.com

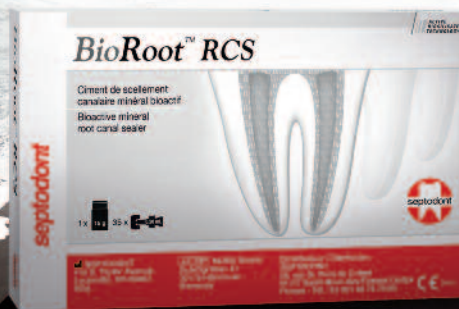

OBTURATION
INNOVATION

BioRoot™ RCS

Root Canal Sealer

High seal, and much more



/// ACTIVE
BIOSILICATE
TECHNOLOGY

We know that failure of a root canal treatment can have severe consequences for you and your patients.

With BioRoot™ RCS, move to a new generation of mineral obturation offering you an innovative combination of features:

- High Seal
- Antimicrobial properties
- Promotes peri-apical healing
- Easy obturations and follow-up

BioRoot™ RCS. **Succeed.**

